



## Protocol for the Examination of Resection Specimens From Patients With Gastrointestinal Stromal Tumor (GIST)

**Version:** 4.3.0.0

**Protocol Posting Date:** December 2022

**CAP Laboratory Accreditation Program Protocol Required Use Date:** September 2023

The changes included in this current protocol version affect accreditation requirements. The new deadline for implementing this protocol version is reflected in the above accreditation date.

**For accreditation purposes, this protocol should be used for the following procedures and tumor types:**

Procedure	Description
Resection	
Tumor Type	Description
Gastrointestinal stromal tumor	

**This protocol is NOT required for accreditation purposes for the following:**

Procedure
Biopsy
Local excision
Primary resection specimen with no residual tumor (eg, following neoadjuvant therapy)
Cytologic specimens

### Authors

Julie C. Fanburg-Smith, MD, FCAP\*; Andrew M. Bellizzi, MD\*; Julia A. Bridge, MD, FCAP\*; Paari Murugan, MD, FCAP\*; Javier A. Laurini, MD; Markku Miettinen, MD.

With guidance from the CAP Cancer and CAP Pathology Electronic Reporting Committees.

\* Denotes primary author.

### Accreditation Requirements

This protocol can be utilized for a variety of procedures and tumor types for clinical care purposes. For accreditation purposes, only the definitive primary cancer resection specimen is required to have the core and conditional data elements reported in a synoptic format.

- Core data elements are required in reports to adequately describe appropriate malignancies. For accreditation purposes, essential data elements must be reported in all instances, even if the response is “not applicable” or “cannot be determined.”
- Conditional data elements are only required to be reported if applicable as delineated in the protocol. For instance, the total number of lymph nodes examined must be reported, but only if nodes are present in the specimen.
- Optional data elements are identified with “+” and although not required for CAP accreditation purposes, may be considered for reporting as determined by local practice standards.

The use of this protocol is not required for recurrent tumors or for metastatic tumors that are resected at a different time than the primary tumor. Use of this protocol is also not required for pathology reviews performed at a second institution (ie, secondary consultation, second opinion, or review of outside case at second institution).

### Synoptic Reporting

All core and conditionally required data elements outlined on the surgical case summary from this cancer protocol must be displayed in synoptic report format. Synoptic format is defined as:

- Data element: followed by its answer (response), outline format without the paired Data element: Response format is NOT considered synoptic.
- The data element should be represented in the report as it is listed in the case summary. The response for any data element may be modified from those listed in the case summary, including “Cannot be determined” if appropriate.
- Each diagnostic parameter pair (Data element: Response) is listed on a separate line or in a tabular format to achieve visual separation. The following exceptions are allowed to be listed on one line:
  - Anatomic site or specimen, laterality, and procedure
  - Pathologic Stage Classification (pTNM) elements
  - Negative margins, as long as all negative margins are specifically enumerated where applicable
- The synoptic portion of the report can appear in the diagnosis section of the pathology report, at the end of the report or in a separate section, but all Data element: Responses must be listed together in one location

Organizations and pathologists may choose to list the required elements in any order, use additional methods in order to enhance or achieve visual separation, or add optional items within the synoptic report. The report may have required elements in a summary format elsewhere in the report IN ADDITION TO but not as replacement for the synoptic report ie, all required elements must be in the synoptic portion of the report in the format defined above.

**Summary of Changes**

**v 4.3.0.0**

- Added Associated Syndrome under Clinical
- Reformatted Tumor Site
- Added BRAF to Special Studies
- Updated Note D Table 1 correction of Gastric moderate rate changed from 10% to 12%
- Updated pTNM Classification

**Reporting Template**

**Protocol Posting Date: December 2022**

**Select a single response unless otherwise indicated.**

**CASE SUMMARY: (GASTROINTESTINAL STROMAL TUMOR (GIST): Resection)**

**Standard(s): AJCC-UICC 8**

**CLINICAL**

**+Associated Syndrome**

- Carney triad
- Carney-Stratakis syndrome
- Neurofibromatosis type 1
- Familial GIST syndrome
- Other (specify): \_\_\_\_\_
- Not specified

**+Preresection Treatment (select all that apply)**

- No known preresection therapy
- Previous biopsy or surgery (specify): \_\_\_\_\_
- Systemic therapy performed (specify type): \_\_\_\_\_
- Therapy performed, type not specified
- Not specified

**SPECIMEN**

**Procedure**

- Local excision
- Resection (specify type, eg., partial gastrectomy): \_\_\_\_\_
- Metastasectomy
- Other (specify): \_\_\_\_\_
- Not specified

**TUMOR**

**Tumor Focality**

- Unifocal
- Multifocal

**Number of Tumors**

- Specify number: \_\_\_\_\_
- Other (specify): \_\_\_\_\_
- Cannot be determined: \_\_\_\_\_

**Sizes of Tumors: \_\_\_\_\_**

- Cannot be determined: \_\_\_\_\_

**Multiple Primary Sites (eg., stomach and small intestine)**

- Not applicable (no additional primary site(s) present)

\_\_\_ Present: \_\_\_\_\_

*Please complete a separate checklist for each primary site*

**Tumor Site (Note [A](#))**

\_\_\_ Esophagus (specify location): \_\_\_\_\_

\_\_\_ Gastroesophageal junction: \_\_\_\_\_

\_\_\_ Stomach (specify location): \_\_\_\_\_

\_\_\_ Small intestine

\_\_\_ Duodenum

\_\_\_ Jejunum

\_\_\_ Ileum (excluding ileocecal valve)

\_\_\_ Meckel diverticulum (site of neoplasm)

\_\_\_ Small intestine, NOS

\_\_\_ Appendix: \_\_\_\_\_

\_\_\_ Ileocecal valve: \_\_\_\_\_

\_\_\_ Large intestine

\_\_\_ Cecum

\_\_\_ Ascending colon

\_\_\_ Hepatic flexure of colon

\_\_\_ Transverse colon

\_\_\_ Splenic flexure of colon

\_\_\_ Descending colon

\_\_\_ Sigmoid colon

\_\_\_ Rectosigmoid junction: \_\_\_\_\_

\_\_\_ Rectum: \_\_\_\_\_

\_\_\_ Large intestine, NOS

\_\_\_ Retroperitoneum: \_\_\_\_\_

\_\_\_ Peritoneum / abdomen (specify site): \_\_\_\_\_

\_\_\_ Other (specify): \_\_\_\_\_

\_\_\_ Cannot be determined: \_\_\_\_\_

\_\_\_ Not specified

**Histologic Type**

\_\_\_ Gastrointestinal stromal tumor, spindle cell type

\_\_\_ Gastrointestinal stromal tumor, epithelioid type

\_\_\_ Gastrointestinal stromal tumor, mixed

\_\_\_ Gastrointestinal stromal tumor, other (specify): \_\_\_\_\_

**+Histologic Type Comment:** \_\_\_\_\_

**Tumor Size (based on clinicoradiologic estimate)**

\_\_\_ Greatest dimension in Centimeters (cm): \_\_\_\_\_ cm

**+Additional Dimension in Centimeters (cm):** \_\_\_ x \_\_\_ cm

\_\_\_ Cannot be determined (explain): \_\_\_\_\_

**Mitotic Rate (Note B)**

*The mitotic rate should be determined in 5 mm<sup>2</sup> of tumor. With the use of older model microscopes, 50 HPF is equivalent to 5 mm<sup>2</sup>. Most modern microscopes with wider fields require approximately 20 to 25 HPF to encompass 5 mm<sup>2</sup>. If necessary, please measure a field of view to accurately determine actual number of fields required to be counted on individual microscopes to encompass 5 mm<sup>2</sup>.*

\_\_\_ Specify mitotic rate per 5 mm<sup>2</sup>: \_\_\_\_\_ mitoses per 5 mm<sup>2</sup>

\_\_\_ Other (specify): \_\_\_\_\_

\_\_\_ Cannot be determined (explain): \_\_\_\_\_

**Histologic Grade (Note B)**

\_\_\_ G1, low grade (mitotic rate less than or equal to 5 per 5 mm<sup>2</sup>)

\_\_\_ G2, high grade (mitotic rate greater than 5 per 5 mm<sup>2</sup>)

\_\_\_ Other (specify): \_\_\_\_\_

\_\_\_ GX, cannot be assessed: \_\_\_\_\_

**+Necrosis**

\_\_\_ Not identified

\_\_\_ Present

**+Extent of Necrosis**

\_\_\_ Specify percentage: \_\_\_\_\_ %

\_\_\_ Other (specify): \_\_\_\_\_

\_\_\_ Cannot be determined: \_\_\_\_\_

\_\_\_ Cannot be determined: \_\_\_\_\_

**Treatment Effect (Note C)**

\_\_\_ No known presurgical therapy

\_\_\_ Not identified

\_\_\_ Present

**+Percentage of Viable Tumor**

\_\_\_ Specify percentage: \_\_\_\_\_ %

\_\_\_ Other (specify): \_\_\_\_\_

\_\_\_ Cannot be determined: \_\_\_\_\_

\_\_\_ Cannot be determined: \_\_\_\_\_

**Risk Assessment (Note D)**

\_\_\_ None

\_\_\_ Very low risk

\_\_\_ Low risk

\_\_\_ Moderate risk

\_\_\_ High risk

\_\_\_ Overtly malignant / metastatic

\_\_\_ Cannot be determined: \_\_\_\_\_

**+Tumor Comment:** \_\_\_\_\_

**MARGINS**

**Margin Status**

All margins negative for GIST

**Closest Margin(s) to GIST (select all that apply)**

- Proximal: \_\_\_\_\_
- Distal: \_\_\_\_\_
- Omental (radial): \_\_\_\_\_
- Mucosal: \_\_\_\_\_
- Deep: \_\_\_\_\_
- Other (specify): \_\_\_\_\_
- Cannot be determined: \_\_\_\_\_

**Distance from GIST to Closest Margin**

*Specify in Centimeters (cm)*

- Exact distance in cm: \_\_\_\_\_ cm
- Greater than 1 cm

*Specify in Millimeters (mm)*

- Exact distance in mm: \_\_\_\_\_ mm
- Greater than 10 mm

*Other*

- Other (specify): \_\_\_\_\_
- Cannot be determined: \_\_\_\_\_

GIST present at margin

**Margin(s) Involved by GIST (select all that apply)**

- Proximal: \_\_\_\_\_
- Distal: \_\_\_\_\_
- Omental (radial): \_\_\_\_\_
- Mucosal: \_\_\_\_\_
- Deep: \_\_\_\_\_
- Other (specify): \_\_\_\_\_
- Cannot be determined: \_\_\_\_\_
- Other (specify): \_\_\_\_\_
- Cannot be determined (explain): \_\_\_\_\_
- Not applicable

**+Margin Comment:** \_\_\_\_\_

**REGIONAL LYMPH NODES (Note [E](#))**

**Regional Lymph Node Status**

- Not applicable (no regional lymph nodes submitted or found)
- Regional lymph nodes present
  - All regional lymph nodes negative for tumor
  - Tumor present in regional lymph node(s)

**Number of Lymph Nodes with Tumor**

- Exact number (specify): \_\_\_\_\_
- At least (specify): \_\_\_\_\_
- Other (specify): \_\_\_\_\_

Cannot be determined (explain): \_\_\_\_\_

Other (specify): \_\_\_\_\_

Cannot be determined (explain): \_\_\_\_\_

**Number of Lymph Nodes Examined**

Exact number (specify): \_\_\_\_\_

At least (specify): \_\_\_\_\_

Other (specify): \_\_\_\_\_

Cannot be determined (explain): \_\_\_\_\_

**+Regional Lymph Node Comment:** \_\_\_\_\_

**DISTANT METASTASIS**

**Distant Site(s) Involved, if applicable (select all that apply)**

Not applicable

Liver: \_\_\_\_\_

Other (specify): \_\_\_\_\_

Cannot be determined

**pTNM CLASSIFICATION (AJCC 8th Edition) (Note [F](#))**

*Reporting of pT, pN, and (when applicable) pM categories is based on information available to the pathologist at the time the report is issued. As per the AJCC (Chapter 1, 8th Ed.) it is the managing physician's responsibility to establish the final pathologic stage based upon all pertinent information, including but potentially not limited to this pathology report.*

**Modified Classification (required only if applicable) (select all that apply)**

Not applicable

y (post-neoadjuvant therapy)

r (recurrence)

**pT Category**

pT not assigned (cannot be determined based on available pathological information)

pT0: No evidence of primary tumor

pT1: Tumor 2 cm or less

pT2: Tumor more than 2 cm but not more than 5 cm

pT3: Tumor more than 5 cm but not more than 10 cm

pT4: Tumor more than 10 cm in greatest dimension

**T Suffix (required only if applicable)**

Not applicable

(m) Multiple primary synchronous tumors in a single organ

**pN Category (Notes [E](#),[F](#))**

*# When no lymph nodes are present (as is often the case with resection for GIST), the pathologic 'N' category is not assigned (pNX is not used for GIST) and should not be reported.*

pN not assigned (no nodes submitted or found)

pN not assigned (cannot be determined based on available pathological information)

pN0: No regional lymph node metastasis

pN1: Regional lymph node metastasis



**pM Category (required only if confirmed pathologically) (Notes E,E)**

\_\_\_ Not applicable - pM cannot be determined from the submitted specimen(s)

\_\_\_ pM1: Distant metastasis

**ADDITIONAL FINDINGS**

**+Additional Findings (specify):** \_\_\_\_\_

**SPECIAL STUDIES (Note G)**

*The CAP GIST Biomarker Template can be used for reporting biomarkers requested.*

**+Immunohistochemical Studies (select all that apply)**

\_\_\_ Not performed: \_\_\_\_\_

\_\_\_ KIT (CD117)

**KIT (CD117)**

\_\_\_ Positive

\_\_\_ Negative

\_\_\_ Pending

\_\_\_ DOG1 (ANO1)

**DOG1 (ANO1)**

\_\_\_ Positive

\_\_\_ Negative

\_\_\_ Pending

\_\_\_ SDHA

**SDHA**

\_\_\_ Intact

\_\_\_ Deficient

\_\_\_ Pending

\_\_\_ SDHB

**SDHB**

\_\_\_ Intact

\_\_\_ Deficient

\_\_\_ Pending

\_\_\_ BRAF

**BRAF**

\_\_\_ Positive

\_\_\_ Negative

\_\_\_ Pending

\_\_\_ Other (specify): \_\_\_\_\_

**+Molecular Genetic Studies (eg., KIT, PDGFRA, SDHA / B / C / D, RAS, or NF1 mutational analysis or BRAF or FGFR1 fusion gene analysis)**

\_\_\_ Performed, see biomarker report: \_\_\_\_\_

\_\_\_ Performed (specify method(s) and result(s)): \_\_\_\_\_

\_\_\_ Pending

\_\_\_ Not performed

CAP Approved

Stomach.GIST\_4.3.0.0.REL\_CAPCP

**COMMENTS**

**Comment(s):** \_\_\_\_\_

## Explanatory Notes

---

### A. Location

Gastrointestinal stromal tumors may occur anywhere along the entire length of the tubal gut, as well as in extravisceral locations, which include the omentum, mesentery, pelvis, and retroperitoneum.<sup>1,2,3,4,5,6</sup> Typically, these tumors arise from the wall of the gut and extend inward toward the mucosa, outward toward the serosa, or in both directions. Lesions that involve the wall of the gastrointestinal (GI) tract frequently cause ulceration of the overlying mucosa. Infrequently, lesions invade through the muscularis mucosa to involve the mucosa. Mucosal invasion is an adverse prognostic factor in numerous studies. Because the anatomic location along the GI tract affects prognosis, with location in the stomach having a more favorable prognosis, it is very important to specify anatomic location as precisely as possible.<sup>5,6</sup>

### References

1. Fletcher CD, Berman JJ, Corless C, et al. Diagnosis of gastrointestinal stromal tumors: a consensus approach. *Hum Pathol*. 2002;33(5):459-465.
2. Miettinen M, Lasota J. Gastrointestinal stromal tumors: definition, clinical, histological, immunohistochemical, and molecular genetic features and differential diagnosis. *Virchows Arch*. 2001;438(1):1-12.
3. Reith JD, Goldblum JR, Lyles RH, Weiss SW. Extragastric (soft tissue) stromal tumors: an analysis of 48 cases with emphasis on histologic predictors of outcome. *Mod Pathol*. 2000;13(5):577-585.
4. WHO Classification of Tumours Editorial Board. Digestive system tumours. Lyon (France): International Agency for Research on Cancer; 2019. (WHO classification of tumours series, 5th ed; vol. 1).
5. Miettinen M, Sobin LH, Lasota J. Gastrointestinal stromal tumors of the stomach: a clinicopathologic, immunohistochemical, and molecular genetic study of 1765 cases with long-term follow-up. *Am J Surg Pathol*. 2005;29(1):52-68.
6. Miettinen M, Felisiak-Golabek A, Wang Z, Inaguma S, Lasota J. GIST Manifesting as a Retroperitoneal Tumor: Clinicopathologic Immunohistochemical, and Molecular Genetic Study of 112 Cases. *Am J Surg Pathol*. 2017 May;41(5):577-585. PMID: 28288036

### B. Histologic Grade

Histologic grading in GIST, unlike in soft tissue sarcoma, only takes mitotic rate into account. GIST is generally less proliferative than many other soft tissue tumors and the threshold for separating low from high-grade tumors occurs at 5 mitotic figures per 5 mm<sup>2</sup>.<sup>1,2,3</sup>

GX: Grade cannot be assessed

G1: Low grade; mitotic rate  $\leq 5/5$  mm<sup>2</sup>

G2: High grade; mitotic rate  $>5/5$  mm<sup>2</sup>

The mitotic count should be initiated in an area that on screening magnification reveals the highest level of mitotic activity and be performed as consecutive high-power fields (HPF). Stringent criteria should be applied when counting mitotic figures; pyknotic or apoptotic nuclei should not be regarded as mitosis.

Note: Mitoses should be counted in 5 mm<sup>2</sup> of tumor.<sup>2,3</sup> With the use of older model microscopes, 50 HPF is equivalent to 5 mm<sup>2</sup>. Most modern microscopes with wider fields require approximately 20 to 25 HPF to

encompass 5 mm<sup>2</sup>. If necessary, please measure a field of view to accurately determine an actual number of fields required to be counted on individual microscopes to encompass 5 mm<sup>2</sup>.

#### References

1. Amin MB, Edge SB, Greene FL, et al, eds. AJCC Cancer Staging Manual. 8th ed. New York, NY: Springer; 2017.
2. Miettinen M, Lasota J. Gastrointestinal stromal tumors: pathology and prognosis at different sites. *Semin Diagn Pathol.* 2006;23(2):70-83.
3. WHO Classification of Tumours Editorial Board. Digestive system tumours. Lyon (France): International Agency for Research on Cancer; 2019. (WHO classification of tumours series, 5th ed; vol. 1).

#### C. Treatment Effect

Gastrointestinal stromal tumors respond well to the newer targeted systemic therapies, imatinib mesylate, and sunitinib malate. The types of treatment effects that have been seen are hypocellularity, myxoid stroma, fibrosis, and necrosis. Nests of viable tumor cells are virtually always seen. Because all of these histologic features can be seen in untreated GIST, it is not possible to know whether they are due to treatment or not. As a practical compromise, it is best to report the percentage of viable tumor after treatment.

#### D. Risk Assessment

Biopsies are suboptimally positioned for GIST risk stratification as these may not include sufficient tumor (i.e., 5 mm<sup>2</sup>) for mitotic counting and may not sample mitotic “hot spots”. Furthermore, the risk for metastasis or tumor related death presumes that the GIST has been removed. On biopsy, one may attempt to risk stratify a GIST, using location, available material for mitotic count, and clinicoradiologic size into account.

Biopsies are more predictive if overtly high mitotic count/high grade/high risk on biopsy, based on mitoses and clinicoradiologic size yet low mitotic count/low grade on biopsy may underestimate actual mitoses on resection and not be accurate due to sampling. Because GIST can recur many years after initial excision, most GIST is now regarded as having at least some potential for distant metastasis. This concept was originally the result of a National Cancer Institute-sponsored consensus conference that was held in 2002.<sup>1</sup> More specific data generated by large follow-up studies refined the biologic potential assessment.<sup>2,3,4,5,6,7</sup> Criteria obtained from those data were adopted in a National Cancer Care Network (NCCN) Task Force report on GIST.<sup>8</sup> We have adopted the criteria for risk stratification, as indicated in Table 1.<sup>2,3,4,5,6,7</sup> The scheme includes anatomic site as a factor because small bowel GIST carries a higher risk of progression than gastric GIST of similar size and mitotic activity. This prognostic assessment applies best to *KIT/PDGFR*A mutant GIST whereas SDH-deficient GIST are more unpredictable.<sup>9</sup> For anatomic sites not listed in this table, such as esophagus, mesentery, and peritoneum, or in the case of “insufficient data,” it is best to use risk criteria for jejunum/ileum.

**Table 1. Guidelines for Risk Assessment of Primary Gastrointestinal Stromal Tumor (GIST)**

Tumor Parameters		Risk of Progressive Disease <sup>#</sup> (%)			
Mitotic Rate	Size	Gastric	Duodenum	Jejunum/Ileum	Rectum
≤5 per 5 mm <sup>2</sup>	≤2 cm	None (0%)	None (0%)	None (0%)	None (0%)
	>2 - ≤5 cm	Very low (1.9%)	Low (8.3%)	Low (4.3%)	Low (8.5%)
	>5 - ≤10 cm	Low (3.6%)	(Insufficient data <sup>##</sup> )	Moderate (24%)	(Insufficient data <sup>##</sup> )
	>10 cm	Moderate (12%)	High (34%)	High (52%)	High (57%)
>5 per 5 mm <sup>2</sup>	≤2 cm	None	(Insufficient data <sup>##</sup> )	High	High (54%)
	>2 - ≤5 cm	Moderate (16%)	High (50%)	High (73%)	High (52%)
	>5 - ≤10 cm	High (55%)	(Insufficient data <sup>##</sup> )	High (85%)	(Insufficient data <sup>##</sup> )
	>10 cm	High (86%)	High (86%)	High (90%)	High (71%)

Adapted with permission from Miettinen and Lasota.<sup>6</sup> Copyright 2006 by Elsevier.

Data based on long-term follow-up of 1055 gastric, 629 small intestinal, 144 duodenal, and 111 rectal GIST from the pre-imatinib era.<sup>2,3,4,6</sup>

<sup>#</sup> Defined as metastasis or tumor-related death

<sup>##</sup> Denotes small number of cases

Note: See Note B, "Histologic Grade," regarding the number of high-power fields to evaluate.

#### References

1. Fletcher CD, Berman JJ, Corless C, et al. Diagnosis of gastrointestinal stromal tumors: a consensus approach. *Hum Pathol*. 2002;33(5):459-465.
2. Miettinen M, Sobin LH, Lasota J. Gastrointestinal stromal tumors of the stomach: a clinicopathologic, immunohistochemical, and molecular genetic study of 1765 cases with long-term follow-up. *Am J Surg Pathol*. 2005;29(1):52-68.
3. Miettinen M, Furlong M, Sarlomo-Rikala M, Burke A, Sobin LH, Lasota J. Gastrointestinal stromal tumors, intramural leiomyomas, and leiomyosarcomas in the rectum and anus: a clinicopathologic, immunohistochemical, and molecular genetic study of 144 cases. *Am J Surg Pathol*. 2001;25(9):1121-1133.
4. Miettinen M, Kopczynski J, Makhlof HR, et al. Gastrointestinal stromal tumors, intramural leiomyomas, and leiomyosarcomas in the duodenum: a clinicopathologic, immunohistochemical, and molecular genetic study of 167 cases. *Am J Surg Pathol*. 2003;27(5):625-641.
5. Miettinen M, Lasota J. Gastrointestinal stromal tumors: pathology and prognosis at different sites. *Semin Diagn Pathol*. 2006;23(2):70-83.
6. Miettinen M, Makhlof H, Sobin LH, Lasota J. Gastrointestinal stromal tumors of the jejunum and ileum: a clinicopathologic, immunohistochemical, and molecular genetic study of 906 cases before imatinib with long-term follow-up. *Am J Surg Pathol*. 2006;30(4):477-489.
7. Miettinen M, Felisiak-Golabek A, Wang Z, Inaguma S, Lasota J. GIST Manifesting as a Retroperitoneal Tumor: Clinicopathologic Immunohistochemical, and Molecular Genetic Study of 112 Cases. *Am J Surg Pathol*. 2017 May;41(5):577-585. PMID: 28288036.
8. Demetri GD, Benjamin RS, Blanke CD, et al; NCCN Task Force. NCCN Task Force report: management of patients with gastrointestinal stromal tumor (GIST)--update of the NCCN clinical practice guidelines. *J Natl Compr Canc Netw*. 2007;5(Suppl 2):S1-S29.

9. WHO Classification of Tumours Editorial Board. Digestive system tumours. Lyon (France): International Agency for Research on Cancer; 2019. (WHO classification of tumours series, 5th ed; vol. 1).

### **E. Regional Lymph Nodes, Metastasis**

Gastrointestinal stromal tumors generally metastasize to a very limited subset of anatomic sites.<sup>1</sup> These tumors rarely metastasize to lymph nodes, which is important to note because lymphadenectomy is unnecessary except in rare circumstances when an enlarged or otherwise suspicious lymph node is encountered. Gastrointestinal stromal tumors metastasize predominantly to the liver or to the peritoneal surfaces, where there can be disseminated intra-abdominal disease presenting as innumerable metastatic nodules. Very rarely, GIST metastasize to the lungs. This situation is associated with rectal location or very advanced disease.<sup>2</sup> Metastasis to bone has also been documented, but it is very rare.

#### References

1. Fletcher CD, Berman JJ, Corless C, et al. Diagnosis of gastrointestinal stromal tumors: a consensus approach. *Hum Pathol.* 2002;33(5):459-465.
2. Miettinen M, Furlong M, Sarlomo-Rikala M, Burke A, Sobin LH, Lasota J. Gastrointestinal stromal tumors, intramural leiomyomas, and leiomyosarcomas in the rectum and anus: a clinicopathologic, immunohistochemical, and molecular genetic study of 144 cases. *Am J Surg Pathol.* 2001;25(9):1121-1133.

### **F. Pathologic Stage Classification**

The American Joint Committee on Cancer (AJCC) and International Union Against Cancer (UICC) GIST staging system is recommended.<sup>1</sup> The staging system should not be applied to pediatric GIST, familial GIST (germline mutant *KIT* or *PDGFRA*) or syndromic GIST (GIST arising in the setting of neurofibromatosis type 1, Carney triad, or Carney dyad also known as Carney-Stratakis syndrome).

#### **TNM Descriptors**

For identification of special cases of TNM or pTNM classifications, the “m” suffix and “y” and “r” prefixes are used. Although they do not affect the stage grouping, they indicate cases needing separate analysis.

The “m” suffix indicates the presence of multiple primary tumors in a single site and is recorded in parentheses: pT(m)NM.

The “y” prefix indicates those cases in which classification is performed during or after initial multimodality therapy (i.e., neoadjuvant chemotherapy, radiation therapy, or both chemotherapy and radiation therapy). The cTNM or pTNM category is identified by a “y” prefix. The ycTNM or ypTNM categorizes the extent of tumor actually present at the time of that examination. The “y” categorization is not an estimate of tumor before multimodality therapy (i.e., before initiation of neoadjuvant therapy).

The “r” prefix indicates a recurrent tumor when staged after a documented disease-free interval and is identified by the “r” prefix: rTNM.

#### **T Category Considerations**

In the case of ruptured tumors, estimates of tumor size can be obtained from radiologic data, if available.

**N Category Considerations**

Regional nodal metastasis is extremely rare in GIST, and there is no routine indication for lymph node biopsy or lymph node dissection. When no lymph nodes are resected or present in the specimen (as is often the case with resections for GIST), the pathologic 'N' category is not assigned; pNX should not be used.

**M Category Considerations**

Most GIST metastasizes to intra-abdominal soft tissues, liver, or both. Intra-abdominal metastasis refers to tumor involvement in the abdominal cavity away from the primary mass. Such metastasis is usually to the serosal surfaces of the abdomen, pelvis, and retroperitoneum. Multiple primary tumors can be seen in the setting of neurofibromatosis type 1 or familial GIST syndrome and should not be considered intra-abdominal metastasis. Rare cases of multiple independent GIST at different GI locations have been reported. In the absence of a primary gastrointestinal GIST, solitary omental, mesenteric, pelvic, or retroperitoneal GIST should be considered primary tumors because extra-gastrointestinal GIST has been described. Liver metastasis implies the presence of metastatic tumor inside the liver parenchyma as one or more nodules. Adherence to liver capsule, even if extensive, as sometimes seen in gastric GIST, should not be considered liver metastasis.

**Stage Groupings:**

Although T, N, and M definitions are identical for all GIST, separate stage grouping schemes are provided for gastric and small intestinal tumors. Primary omental GIST should follow the gastric GIST staging group scheme. GIST arising in other locations (i.e., mesentery, esophagus, colon, and rectum) are to follow the small intestinal group staging scheme.

**References**

1. Amin MB, Edge SB, Greene FL, et al, eds. AJCC Cancer Staging Manual. 8th ed. New York, NY: Springer; 2017.

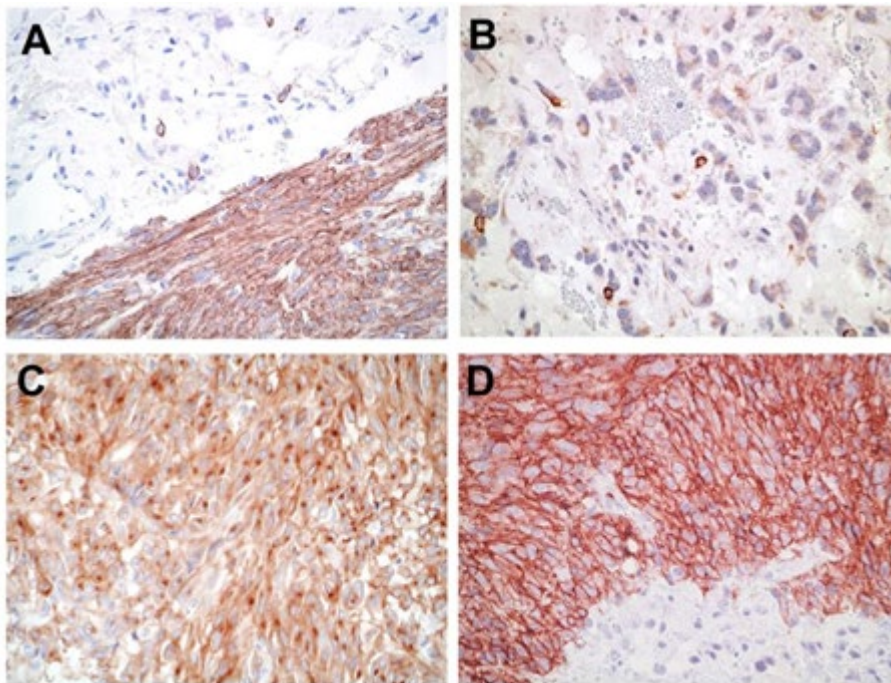
**G. Ancillary Studies****Immunohistochemistry**

Because small-molecule kinase inhibitor therapy is highly effective in the treatment of GIST, it has become imperative to distinguish GIST from its histologic mimics, mainly leiomyoma, leiomyosarcoma, schwannoma, and desmoid fibromatosis.<sup>1,2</sup> Immunohistochemistry is instrumental in the work up of GIST. For the initial workup of GIST, a basic immunohistochemical panel including CD117 (KIT), DOG1 (Ano1), Desmin, S100 protein, and CD34 is recommended. GIST is immunoreactive for KIT (CD117) (approximately 95%) and/or DOG1(>99%).<sup>3,4,5</sup> KIT immunoreactivity is usually strong and diffuse but can be more focal in unusual cases (Figure 1, A and B). It is not unusual for GIST to exhibit dot-like perinuclear staining (Figure 1, C), while less commonly, some cases exhibit membranous staining (Figure 1, D). These patterns do not clearly correlate with mutation type or response to therapy. Most KIT-negative/DOG1-positive GIST is gastric or extra-visceral GIST and almost invariably harbor a platelet-derived growth factor receptor A (*PDGFRA*) mutation.<sup>6</sup> DOG1 expression is not related to mutational status in GIST, and it may be a useful marker to identify a subset of patients with CD117-negative GIST, who might benefit from targeted therapy.<sup>4,5</sup> Approximately 70% of GIST are positive for CD34, 30% to 40% are positive for smooth muscle actin, 5% are positive for S100 protein (usually focal), 5% are positive for desmin (usually focal), and 1% to 2% are positive for keratin (weak/focal).<sup>7</sup>



Note: PanTrk immunohistochemistry may be positive in GIST, a tumor typically negative for *NTRK* fusion, and this immunostain is not recommended.

Since succinate dehydrogenase (SDH)-deficient GIST may be familial, has specific implications (see the following), it is recommended that all gastric GIST be screened for loss of SDH by immunohistochemistry, best accomplished by immunostaining for SDHB, which is lost in all independent of the SDH-subunit that is inactivated.<sup>8,9,10,11</sup> Mutations in SDHA are detected in 30% of SDH-deficient GIST and loss of expression of SDHA specifically identifies tumors with SDHA mutations; other SDH-deficient GIST show normal (intact) cytoplasmic staining for SDHA.<sup>12,13</sup> Patients with SDH-deficient GIST should be referred to a genetic counselor for appropriate work up.



**Figure 1.** Patterns of KIT staining in gastrointestinal stromal tumor (GIST). A. Diffuse and strong immunoreactivity in a typical GIST. B. Focal and weak pattern in an epithelioid gastric GIST with a *PDGFRA* mutation. C. Dot-like perinuclear staining. D. Membranous pattern. (Original magnification X400)

### **Molecular Analysis**

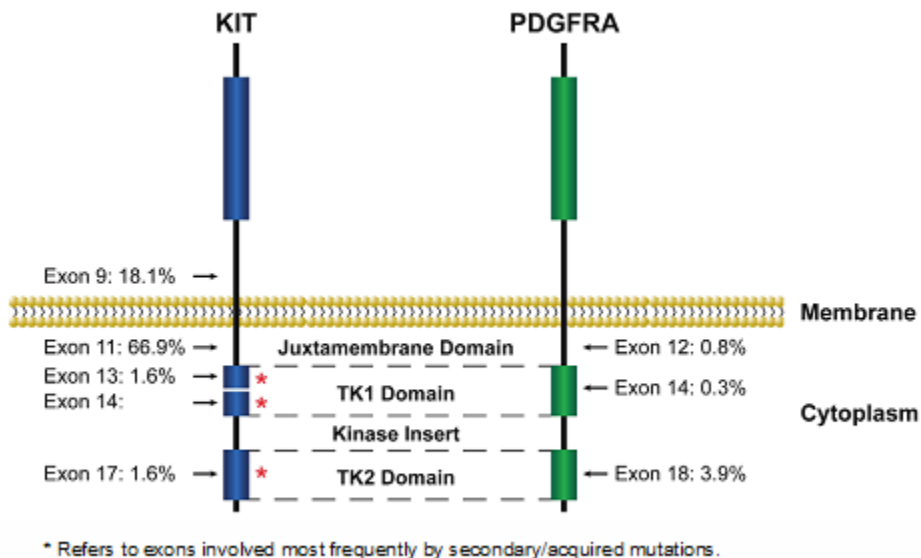
Approximately 75% of GIST possess activating mutations in the *KIT* gene, whereas another 10% have activating mutations in the *PDGFRA* gene.<sup>14,15,16,17</sup> These mutations result in virtually full-length *KIT* proteins that exhibit ligand-independent activation. *KIT* and *PDGFRA* each contain 21 exons. However, mutations cluster within “hotspots”: exons 9, 11, 13, and 17 in *KIT*, and exons 12, 14, and 18 in *PDGFRA* (Figure 2). About 5% to 10% of GIST appear to be negative for both *KIT* and *PDGFRA* mutations. The most recent NCCN Task Force on GIST strongly encourages that *KIT* and *PDGFRA* mutational analysis be performed if tyrosine kinase inhibitors (TKIs) are considered as part of the treatment plan for unresectable or metastatic disease and that mutational analysis be considered for patients with primary disease, particularly those with high-risk tumors. *KIT* and *PDGFRA* mutation status can be determined easily from paraffin-embedded tissue. Secondary or acquired mutations can be associated with development of tumor resistance in the setting of long-term imatinib mesylate treatment. These are usually point mutations that occur most commonly in *KIT* exons 13, 14, and 17.<sup>18</sup> The clinical utility of



these mutations is an evolving concept, but it is important not to confuse them with the primary or initial mutation in GIST.

Recent studies focusing on the molecular classification of GIST recognized two major subgroups: succinate dehydrogenase (SHD)-competent and SDH-deficient GIST, both of which can arise in the sporadic or familial setting.<sup>8,9</sup> SDH-competent GIST include tumors with mutations of *KIT* and *PDGFRA* as well as a subset of wild-type GIST with mutations mainly in *NF1* and *BRAF* genes or rarely fusion gene events involving *FGFR1* or *BRAF*.<sup>19,20,21,22,23,24</sup> On the other hand, SDH-deficient GIST includes tumors with a genetic alteration in any of the SDH subunits leading to SDH dysfunction.

SDH-deficient GIST represents approximately 8% of GIST; although, these may arise sporadically. The majority of pediatric GIST arise in Carney triad and Carney-Stratakis syndrome and are SDH-deficient. SDH is a mitochondrial enzyme comprising four subunits (SDHA, SDHB, SDHC, and SDHD) that are involved in the Krebs cycle. Genetic alteration of any of the four subunits results in SDH dysfunction and subsequent loss of SDHB expression by immunohistochemistry. SDH-deficient GIST arises almost exclusively in the stomach, affects predominantly female patients, and tends to manifest at a young age. Pathologic features associated with SDH-deficient tumors include multinodular and/or plexiform growth pattern, epithelioid morphology, lymphovascular invasion, nodal involvement, and frequent metastasis to the liver and peritoneum. Importantly, germline mutations in the genes coding for any of the SDH subunits can lead to paragangliomas/pheochromocytomas, SDH-deficient renal cell carcinoma, and pituitary tumors in addition to GIST. It is recommended that all gastric GIST be screened for loss of SDHB by immunohistochemistry. All patients with SDH-deficient GIST identified by loss of SDHB immunostain should be referred to a genetic counselor.



**Figure 2.** Locations and frequency of activating *KIT* and *PDGFRA* mutations in GIST. Adapted with permission from Heinrich et al.<sup>14</sup> Copyright 2003 by the American Society of Clinical Oncology. All rights reserved.

*KIT* and *PDGFRA* are excellent targets for small-molecule tyrosine kinase inhibitors, and two compounds of this class, imatinib mesylate (Gleevec, Novartis Pharmaceuticals, Basel, Switzerland) and sunitinib

malate (Sutent, Pfizer Pharmaceuticals, New York, New York), avapritinib (Ayvakit, *PDGFRA D842V* (exon 18) mutant, may be resistant to standard therapy), regorfenib (3rd line), ripretinib (4th line, Qinlock) have shown efficacy in clinical trials and have been approved by the US Food and Drug Administration for the treatment of GIST.<sup>25,26,27,28</sup> SDH-deficient GIST is usually resistant to imatinib but may have a higher probability of response to sunitinib.<sup>8,29</sup> Because different tyrosine kinase inhibitors (TKIs) may have differential efficacy depending on the type of mutation present in GIST, oncologists may want to know the mutation status of each GIST<sup>30</sup>, because this may influence which drug the patient receives.<sup>14</sup> Secondary resistance mutations may also affect drug selection as their significance is further defined.

#### References

1. Hornick JL, Fletcher CD. Immunohistochemical staining for KIT (CD117) in soft tissue sarcomas is very limited in distribution. *Am J Clin Pathol*. 2002;117(2):188-193.
2. Miettinen M, Sobin LH, Sarlomo-Rikala M. Immunohistochemical spectrum of GISTs at different sites and their differential diagnosis with a reference to CD117 (KIT). *Mod Pathol*. 2000;13(10):1134-1142.
3. Sarlomo-Rikala M, Kovatich AJ, Barusevicius A, Miettinen M. CD117: a sensitive marker for gastrointestinal stromal tumors that is more specific than CD34. *Mod Pathol*. 1998;11(8):728-734.
4. Espinosa I, Lee CH, Kim MK, et al. A novel monoclonal antibody against DOG1 is a sensitive and specific marker for gastrointestinal stromal tumors. *Am J Surg Pathol*. 2008;32(2):210–218.
5. Miettinen M, Wang ZF, Lasota J. DOG1 antibody in the differential diagnosis of gastrointestinal stromal tumors: a study of 1840 cases. *Am J Surg Pathol*. 2009;33:1401–1408.
6. Medeiros F, Corless CL, Duensing A, et al. KIT-negative gastrointestinal stromal tumors: proof of concept and therapeutic implications. *Am J Surg Pathol*. 2004;28(7):889-894.
7. Fletcher CD, Berman JJ, Corless C, et al. Diagnosis of gastrointestinal stromal tumors: a consensus approach. *Hum Pathol*. 2002;33(5):459-465.
8. Mei L, Smith SC, Faber AC, et al. Gastrointestinal Stromal Tumors: The GIST of Precision Medicine. *Trends Cancer*. 2018;4:74-91.
9. Gill AJ. Succinate dehydrogenase (SDH) and mitochondrial driven neoplasia. *Pathology*. 2012 Jun;44(4):285-92.
10. Gill AJ, Benn DE, Chou A, et al. Immunohistochemistry for SDHB triages genetic testing of SDHB, SDHC, and SDHD in paraganglioma-pheochromocytoma syndromes. *Hum Pathol*. 2010 Jun;41(6):805-14.
11. Doyle LA, Nelson D, Heinrich MC, et al. Loss of succinate dehydrogenase subunit B (SDHB) expression is limited to a distinctive subset of gastric wild-type gastrointestinal stromal tumors: a comprehensive genotype-phenotype correlation study. *Histopathology*. 2012;61(5):801-809.
12. Wagner AJ, Remillard SP, Zhang YX, et al. Loss of expression of SDHA predicts SDHA mutations in gastrointestinal stromal tumors. *Mod Pathol*. 2013;26(2):289-294.
13. Dwight T, Benn DE, Clarkson A, et al. Loss of SDHA expression identifies SDHA mutations in succinate dehydrogenase-deficient gastrointestinal stromal tumors. *Am J Surg Pathol*. 2013;37(2):226-233.
14. Heinrich MC, Corless CL, Demetri GD, et al. Kinase mutations and imatinib response in patients with metastatic gastrointestinal stromal tumor. *J Clin Oncol*. 2003;21(23):4342-4349.
15. Heinrich MC, Corless CL, Duensing A, et al. PDGFRA activating mutations in gastrointestinal stromal tumors. *Science*. 2003;299(5607):708-710.
16. Hirota S, Isozaki K, Moriyama Y, et al. Gain-of-function mutations of c-kit in human gastrointestinal stromal tumors. *Science*. 1998;279(5350):577-580.

17. Rubin BP, Singer S, Tsao C, et al. KIT activation is a ubiquitous feature of gastrointestinal stromal tumors. *Cancer Res*. 2001;61(22):8118-8121.
18. Heinrich MC, Corless CL, Blanke CD, et al. Molecular correlates of imatinib resistance in gastrointestinal stromal tumors. *J Clin Oncol*. 2006;24(29):4764-4774.
19. Dare AJ, Gupta AA, Thipphavong S, Miettinen M, Gladdy RA. Abdominal neoplastic manifestations of neurofibromatosis type 1. *Neurooncol Adv*. 2020 Jun 25;2(Suppl 1):i124-i133. doi: 10.1093/noajnl/vdaa032. PMID: 32642738.
20. Lasota J, Kowalik A, Felisiak-Golabek A, Zięba S, Wang ZF, Miettinen M. New Mechanisms of mTOR Pathway Activation in KIT-mutant Malignant GISTs. *Appl Immunohistochem Mol Morphol*. 2019 Jan;27(1):54-58. PMID: 28777148.
21. Shi E, Chmielecki J, Tang CM, et al. FGFR1 and NTRK3 actionable alterations in “wild-type” gastrointestinal stromal tumors. *J Transl Med*. 2016;14(1):339.
22. Pantaleo MA, Urbini M, Indio V, et al. Genome-wide analysis identifies MEN1 and MAX mutations and a neuroendocrine-like molecular heterogeneity in quadruple WT GIST. *Mol Cancer Res*. 2017;15(5):553-562.
23. Charo LM, Burgoyne AM, Fanta PT, Patel H, Chmielecki J, Sicklick JK, McHale MT. A Novel PRKAR1B-BRAF Fusion in Gastrointestinal Stromal Tumor Guides Adjuvant Treatment Decision-Making During Pregnancy. *J Natl Compr Canc Netw* 2018;16:238-42.
24. Torrence D, Xie Z, Zhang L, Chi P, Antonescu CR. Gastrointestinal stromal tumors with BRAF gene fusions. A report of two cases showing low or absent KIT expression resulting in diagnostic pitfalls. *Genes Chromosomes Cancer*. 2021 Dec;60(12):789-795.
25. Demetri GD, Benjamin RS, Blanke CD, et al; NCCN Task Force. NCCN Task Force report: management of patients with gastrointestinal stromal tumor (GIST)--update of the NCCN clinical practice guidelines. *J Natl Compr Canc Netw*. 2007;5(Suppl 2):S1-S29.
26. Demetri GD. Targeting the molecular pathophysiology of gastrointestinal stromal tumors with imatinib: mechanisms, successes, and challenges to rational drug development. *Hematol Oncol Clin North Am*. 2002;16(5):1115-1124.
27. Demetri GD, van Oosterom AT, Garrett CR, et al. Efficacy and safety of sunitinib in patients with advanced gastrointestinal stromal tumour after failure of imatinib: a randomised controlled trial. *Lancet*. 2006;368(9544):1329-1338.
28. Kelly CM, Gutierrez Sainz L, Chi P. The management of metastatic GIST: current standard and investigational therapeutics. *J Hematol Oncol* 14:2, 2021.
29. Glod J, Arnaldez FI, Wiener L, Spencer M, Killian JK, Meltzer P, Dombi E, Derse-Anthony C, Derdak J, Srinivasan R, Linehan WM, Miettinen M, Steinberg SM, Helman L, Widemann BC. A Phase II Trial of Vandetanib in Children and Adults with Succinate Dehydrogenase-Deficient Gastrointestinal Stromal Tumor. *Clin Cancer Res*. 2019 Nov 1;25(21):6302-6308. Epub 2019 Aug 22. PMID: 31439578.
30. Corless CL, Schroeder A, Griffith D, et al. PDGFRA mutations in gastrointestinal stromal tumors: frequency, spectrum and in vitro sensitivity to imatinib. *J Clin Oncol*. 2005;23(23):5357-5364.